



PATIENT

Charlie Da Cunha

SPECIES

Canine

BREED

Havanese Mix

SEX

MN

AGE

14

WEIGHT

9.14kg

INTERPRETED BY

R. McKenzie Daniel,
DVM, DABVP
(Canine and Feline)

IMAGING PERFORMED BY

Dakota Harmon

HOSPITAL NAME

Wilvet Salem

REFERRING VET

Dakota Harmon

INVOICE 24909

DATE
05/22/2026

PRESENTING CLINICAL SIGNS

Patient presents for decreased appetite for several days. Patient presented to rdvm about a week ago for severe diarrhea and decreased appetite. Bloodwork was done and rdvm stated patient has pancreatitis. medications were prescribed along with bland diet. Stools got better but patient has still had decreased appetite.

Abnormal PE/Chem/CBC/UA Results: 5/13/26: Marked elevation in liver values: - AST 90 [N: 15-66 IU/L] - ALT 389 [N: 12-118 IU/L] (previously 376 in December 2025; At WilVet Salem June 2025 during pancreatitis flare, was 599) - ALKP 1508 [N: 5 - 131 IU/L] (previously 898 in December 2025; At WilVet Salem June 2025 during pancreatitis flare, was 1346) - Elevated Precision PSL 234 (lower than previous values, was 367 at WilVet Salem June 2025) - Mild increase to potassium 5.8 [N: 3.6 - 5.5mEq/L] which can be secondary to decrease in appetite. - Mild increase to neutrophils 10,626 [N: 2060 - 10,600/uL] - r/o infection 5/22: CBC: HCT 41.9, WBC 15.73, neut 12.55 (H), lymph 2.11, PLT 537 (H) Chem10: ALT 878 (H), ALP 1872 (H) ePOC: sodium 138 (L), Lactate 4.97 (H), HCT 39 cPL: 334 (H - equivocal range) PT/PTT: 12 (WNL)/94 (WNL)

ULTRASONOGRAPHIC EXAMINATION OF THE ABDOMEN

Urinary System

The urinary bladder, trigone, cystourethral junction, and visible pelvic urethra to a depth of 3 cm exhibited normal thickness and tone. Anechoic urine was present in the lumen with no evidence of urine/lumen sediment, mineral, or calculi. The ureteral papillae were normal. The ureters were not visible which is normal. No evidence of inflammatory or neoplastic changes was noted.

Normal renal size with asymmetrical margination was present in both kidneys. The renal cortex presented uniformly increased in echogenicity with uniform echotexture. The renal cortex appeared to be hypertrophied resulting in an altered cortex: medulla ratio. Moderate to significant loss of corticomedullary distinction was also present. Bilateral areas of pinpoint medullary mineral and cortical cysts were present. The renal medullary volume was subjectively reduced. The left kidney measured 4.7 cm in length. The right kidney measured 5.0 cm in length.

The area of the aortic trifurcation was free of pathology.

The area of the residual prostate appeared normal and free of pathology

Adrenal Glands

The bilateral adrenal glands were indistinctly visualized, subjective normal in size. Mild parenchyma heterogeneity and mild capsule asymmetry was present without suspicion for overt neoplasia. The left adrenal gland subjectively measured 0.64 cm width in the caudal pole. The right adrenal gland subjectively measured 0.66 cm width in the caudal pole.

Spleen

The spleen exhibited a finely textured and homogenous parenchyma which was hyperechoic to the liver and renal cortical parenchyma. The capsule was smooth and regular without apparent expansion. The splenic vasculature at the hilus was normal in volume with no evidence of congestion or thrombosis. Acute to chronic inflammatory, neoplastic, or benign parenchyma changes were not noted.

Liver/Gallbladder



PATIENT

Charlie Da Cunha

SPECIES

Canine

BREED

Havanese Mix

SEX

MN

AGE

14

WEIGHT

9.14kg

INTERPRETED BY

R. McKenzie Daniel,
DVM, DABVP
(Canine and Feline)

IMAGING PERFORMED BY

Dakota Harmon

HOSPITAL NAME

Wilvet Salem

REFERRING VET

Dakota Harmon

INVOICE

24909

DATE

05/22/2026

Marked hepatomegaly, rounded hepatic contour and non-homogenous parenchyma. Heterogeneous focally cystic liver mass occupying majority of the left liver, potentially extending into the right liver, vs possible separate similar appearing right liver mass was present. The mass in the left liver measured ~ 8 cm in diameter, with potential extension of mass vs separate mass in the right liver measuring ~ 8 cm in diameter.

The gallbladder was non-distended in size with thin walls and moderate congealed non-organized gallbladder debris. The cystic and common bile ducts were normal.

Gastrointestinal

The stomach presented intact wall layering with a normal wall layer ratio. The lumen of the stomach was empty with no signs of ileus, obstruction or foreign material.

The small intestine presented intact wall layering with 1:3 muscularis/mucosa ratio. The lumen of the small intestine was empty with no signs of mechanical/metabolic ileus, obstruction or foreign material.

Normal visible colon wall layers were present with apparent formed feces in lumen.

Pancreas

Mildly enlarged non-homogenous pancreas.

Free Abdomen

No omental masses, overt lymphadenopathy or peritoneal effusion was present.

ULTRASONOGRAPHIC FINDINGS

Primary

- Significant hepatomegaly with liver mass/masses
- Immature gallbladder mucocele
- Chronic/ chronic active pancreatitis pattern
- Sonographically normal empty gastrointestinal tract
- Chronic renal changes exhibiting medullary mineral and cortical cysts

INTERPRETATION OF THE FINDINGS & FURTHER RECOMMENDATIONS

Assuming normal clotting status, hepatic mass/parenchyma FNA cytology recommended for further clarification. Hepatic neoplasia probable pending cytology. Empirical therapy for chronic/ chronic active pancreatitis with concurrent gastrointestinal support recommended. Correlation with UA recommended.



PATIENT

Charlie Da Cunha

SPECIES

Canine

BREED

Havanese Mix

SEX

MN

AGE

14

WEIGHT

9.14kg

INTERPRETED BY

R. McKenzie Daniel,
DVM, DABVP
(Canine and Feline)

IMAGING PERFORMED BY

Dakota Harmon

HOSPITAL NAME

Wilvet Salem

REFERRING VET

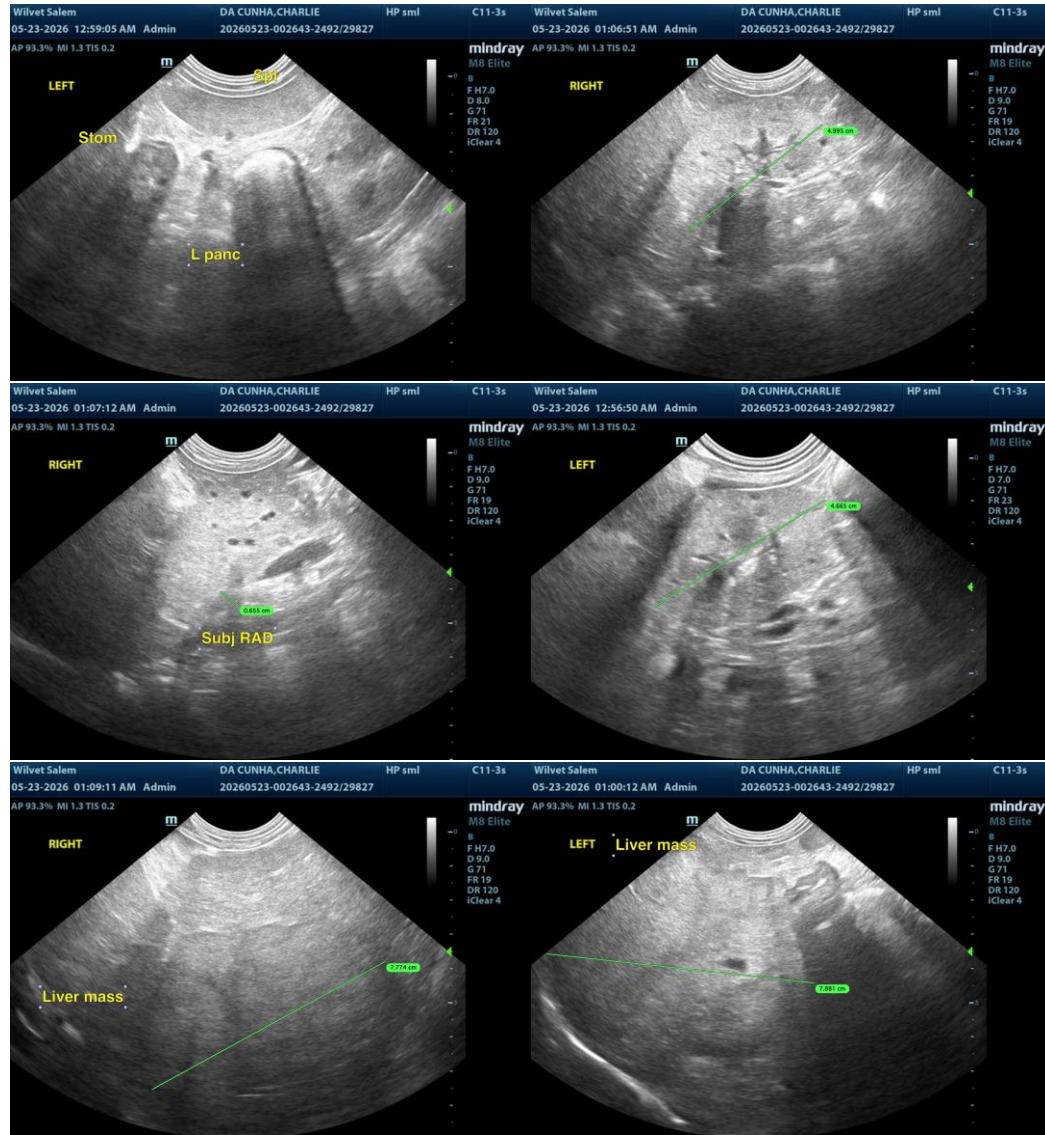
Dakota Harmon

INVOICE

24909

DATE

05/22/2026





PATIENT

Charlie Da Cunha

SPECIES

Canine

BREED

Havanese Mix

SEX

MN

AGE

14

WEIGHT

9.14kg

INTERPRETED BY

R. McKenzie Daniel,
DVM, DABVP
(Canine and Feline)

IMAGING PERFORMED BY

Dakota Harmon

HOSPITAL NAME

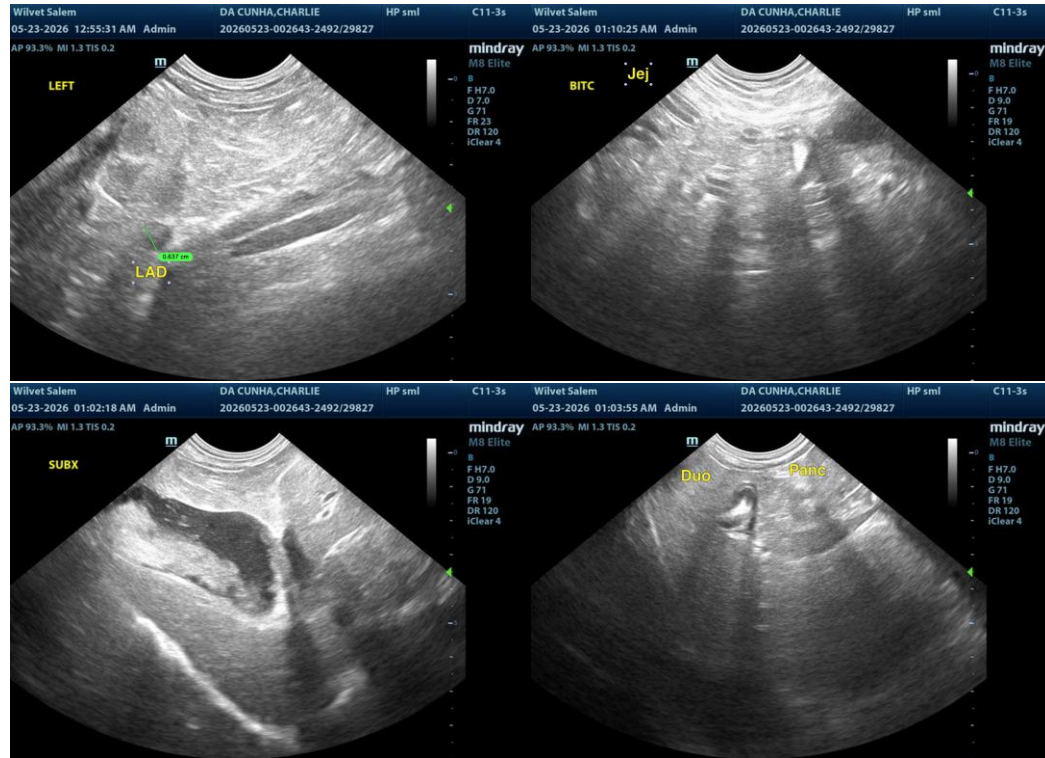
Wilvet Salem

REFERRING VET

Dakota Harmon

INVOICE
24909

DATE
05/22/2026



The information and recommendations provided are based on the images presented by the referring veterinarian/sonographer. No evaluation can be communicated regarding pathology that was not visible in the image/video clips provided.

Thank you for this referral. If the clinical or image interpretation does not parallel your findings or if I can be of any further assistance, please contact me.

R. McKenzie Daniel, DVM, DABVP (Canine/Feline Practice)
info@sonopath.com